neurocritical care society Neurocrit Care (2007) 7:217–220
DOI 10.1007/s12028-007-0066-0

PRACTICAL PEARL

Dexmedetomidine for the treatment of paroxysmal autonomic instability with dystonia

Richard P. Goddeau Jr. · Scott B. Silverman · John R. Sims

Published online: 29 June 2007

Abstract
Introduction A 38-year-old man with severe head trauma complicated by paroxysmal severe intracranial pressure elevation associated with tachypnea, tachycardia, diaphoresis, and extensor posturing was diagnosed as suffering from paroxysmal autonomic instability with dystonia (PAID). These events were unresponsive to standard medical therapy, which included morphine, fentanyl, labetalol, lorazepam, metoprolol, and clonidine.
Methods A trial treatment with dexmedetomidine, a central acting alpha2-agonist, to control symptoms of PAID was initiated 12 days after injury. PAID-related events subsided during the 72-h infusion protocol of 0.2–0.7 mcg/kg/h. No further events were noted after termination of the 72-h infusion.
Conclusions Dexmedetomidine may be a novel pharmacologic agent to aid in abrogating PAID.

Keywords Dexmedetomidine · Sympathetic storming · Paroxysmal autonomic instability with dystonia · Diencephalic seizure · Dysautonomia · Traumatic brain injury

R. P. Goddeau Jr.
Department of Neurology, University of Massachusetts Medical School, Worcester, MA, USA

S. B. Silverman
Department of Neurology, Division of Neurocritical Care and Stroke, Massachusetts General Hospital, Harvard Medical School, Boston, MA, USA

J. R. Sims (✉)
Department of Neurology and Radiology, Division of Neurocritical Care & Stroke, Massachusetts General Hospital, CNY149 Rm6403, Charlestown, MA 02129, USA
e-mail: jsims@partners.org

Introduction

In a recent article, Blackman and colleagues discussed "sympathetic storming" [1]. They suggested the term paroxysmal autonomic instability with dystonia (PAID) and proposed diagnostic criteria for this syndrome. There are few treatment options for this syndrome. We report a case meeting the diagnostic and phenomenological criteria for PAID, which was successfully treated with dexmedetomidine, a selective alpha-2 adrenergic agonist.

Case Report

A 38-year-old man without antecedent medical history was admitted to the neurological intensive care unit (GCS 7, M5V1E1) after falling from a height of 20 feet and suffering left frontal, temporal, and parietal contusions with associated subdural hematoma, a right temporal, and parietal bone fractures (Fig. 1A–C). Phenytoin, for acute seizure prophylaxis, was initiated. An intraparenchymal pressure monitor was placed. The patient required high doses of propofol and fentanyl for sedation, ICP and pain control. Frequent episodes of intermittent elevated intracranial pressure (ICP) (>40 cm H_2O) with a commensurate drop in his cerebral perfusion pressure (CPP) (<60 cm H_2O) prompted the initial use of mannitol and hypertonic (23.4%) saline. Additionally, the intraparenchymal monitor was subsequently replaced with an external ventricular drain (EVD) for cerebrospinal fluid (CSF) drainage.

Although the baseline ICP normalized (5–15 cm H_2O) with continued CSF drainage via EVD, the patient began to have multiple, unprovoked, stereotypic clinical events characterized by tachycardia (rate up to 140 s), tachypnea (rate up to 40 s), diaphoresis, sharp increase in ICP (to 40

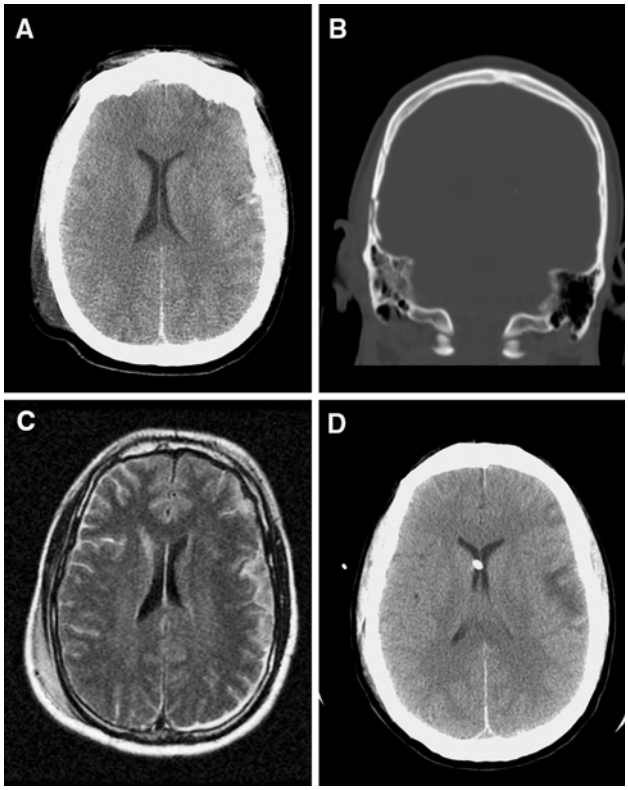

Fig. 1 Cerebral imaging. (**A**) Initial noncontrast head CT shows right subgaleal hematoma with contracoup left frontal contusion with minimal cortical blood. (**B**) Initial reconstruction of head CT with bone windows shows right temporal/parietal fracture. (**C**) MRI (FLAIR) on day of presentation shows slight bilateral subarachnoid hyperintensity consistent with subarachnoid hemorrhage and left frontal cortical hyperintensity consistent with contusion and right parietal subdural hematoma. (**D**) Noncontrast CT, 13 days after injury, show hypodensity in the left frontotemporal insular region and normal ventricles with right ventriculostomy drain in place

from baseline of 5–15 cm H_2O), and extensor posturing. These events began 9 days after traumatic brain injury (TBI). Each event lasted for 1–2 h, recurring 2–3/day. There was no persistent rigidity, hyperreflexia, or ocular ataxia between events. Serial noncontrast head CTs were stable, without hydrocephalus, impending herniation, or additional hemorrhage (Fig. 1D). The CTA of chest showed no evidence of pulmonary emboli. In addition, he underwent multiple EEGs with continuous monitoring which were unrevealing for seizures. No neuroleptic or serotonergic medications were administered. With the persistence of mild hyperthermia despite antibiotics and no infectious source, central or drug fever was considered. Prophylactic phenytoin was weaned without change in hyperthermia or alteration of the paroxysmal events. The patient met suggested criteria for PAID [1].

Initially the events were treated with propofol 300 mg/h and fentanyl citrate 170 mcg/h with prn morphine 2–4 mg and lorazepam 2 mg every 4 h. A labetalol drip was started at 50 mg/h but within 24 h the patient had reached maximum dosage of 120 mg/h. The events continued despite these initial treatments, so clonidine 0.1 mg three times daily, metoprolol 12.5 mg two times daily, and midazolam 5 mg/h was initiated. There appeared to be no clinical response to these medications despite continued propofol 200 mg/h and fentanyl 75 mg/h with continued prn morphine and lorazepam. On the 12th day of hospitalization and 3 days after no response to the above drugs, the patient was started on an infusion of dexmedetomidine, an alpha-2 adrenergic agonist. Metoprolol was discontinued prior to initiation of dexmedetomidine to avoid the possibility of symptomatic bradycardia. The initial dose of dexmedetomidine was 0.2 mcg/kg/h, titrated up to 0.7 mcg/kg/h as needed to abrogate clinically apparent PAID-related events. The patient tolerated the initiation of treatment well without bradycardia. Fentanyl citrate and clonidine were discontinued later that same evening. Propofol was weaned to 100 mg/h 24 h later and discontinued 48 h after dexmedetomidine was started. No further episodic events were witnessed. Concomitant sedative medications were successfully weaned off and the dexmedetomidine was weaned, as per institutional protocol, within 72 h. Interestingly, no further clinical PAID-related events were witnessed even after discontinuation of dexmedetomidine. The patient made a successful transition out of the intensive care unit 24 h after discontinuation of dexmedetomidine.

Discussion

Traumatic brain injury is a common underlying etiology of PAID and can occur in about 10% of TBI patients [2], but tumor [3] and acute hydrocephalus [4] have also been reported to cause PAID. PAID is a clinically distinct entity with well-described features [1]. These phenomena have been called “sympathetic storms,” “dysautonomia,” or “diencephalic seizures,” but the first and second terms are clinically vague and the latter misrepresents the underlying pathophysiology [5]. PAID has been thought to be due to dysfunction at the level of the diencephalon, however, a clear link to a lesion of the diencephalon is not established. Despite this link, there does appear to be a greater chance of developing PAID if a focal lesion is present after TBI. Evidence is building that PAID results from a loss of inhibitory inputs to sympathetic feedback loops (resulting in tachycardia, hypertension, hyperpyrexia, tachypnea, or diaphoresis) and may also result in loss of GABAergic inhibition of cortical projections (resulting in dystonic posturing) [6–8].

Since symptoms of PAID are protean and overlap with other serious conditions commonly found in the ICU setting, a careful evaluation for alternative causes must be

undertaken. Therefore, diagnosis in the acute setting can be difficult. In patients with TBI, paroxysms of spontaneous hypertension and tachypnea often suggest intracranial mass, elevated intracranial pressure, pain or seizures, and/or or autonomic dysregulation from cervical and thoracic spinal cord lesions. Fever, tachypnea and diaphoresis often herald infection, drug reaction, or even deep vein thrombosis with pulmonary embolus. Dystonic or other paroxysmal posturing may suggest increased intracranial pressure, inadequate analgesia, seizure activity or adverse drug reaction. Because the diagnostic criteria of PAID are largely clinical, it remains an important consideration, but it is a diagnosis of exclusion.

Once diagnosed, treatment strategies aim to control the clinical features. Adrenergic disinhibition has been successfully treated with alpha-1 adrenergic or beta adrenergic blockade [1, 9–11]. Additionally, benzodiazepine, opioid agonists, dopamine agonists, intrathecal baclofen, and muscle relaxants have been used [1, 11–13]. A common first-line treatment should include morphine, since this drug is beneficial for treating pain and pulmonary edema, which are commonly found in TBI, morphine has the added benefit of reducing tachycardia and tachypnea. However, we do not believe the current data support opioid receptor dysfunction as a primary etiology behind PAID [6–8], nor do we believe dopaminergic dysfunction is well-supported, despite the use of bromocriptine in the past. Labetalol and clonidine both appear to directly address the likely etiology of sympathetic dysregulation. However, our patient rapidly became unresponsive to labetalol and had no effect with clonidine. Baclofen, a GABA-B agonist, is likely helpful but requires intrathecal administration [13, 14]. Thus, we considered the new drug, Dexmedetomidine, a rapidly titratable, potent, selective alpha-2 agonist, as a potential unique pharmacologic tool in the treatment of PAID. Presynaptic alpha-2 receptor stimulation blocks norepinephrine release and post-synaptic alpha-2 stimulation decreases sympathetic activity [15]. In addition to the adrenergic blockade, it has been shown to be useful in maintaining a sympathovagal balance [16], decreasing need for analgesic coadministration [17], and abrogating post-anesthetic shivering [18].

In our patient, we surmise that he may have developed PAID secondary to swelling and compression of the left insula (Fig 1D). The left insula plays a role in parasympathetic outflow [19, 20]. Dysfunctional parasympathetic outflow may have provided an unregulated sympathetic feedback loop. Our patient's response to dexmedetomidine supports the hypothesis of an over-active sympathetic system. We are uncertain as to why the patient no longer had symptoms after discontinuation, although others have reported abrogation of symptoms after a short 6-day treatment with intrathecal baclofen [14]. However, often symptoms last for weeks or months and subtle cardiac dysregulation can last for over 1 year [6]. However, we think that there may be a reporting and detection bias. In that, PAID is difficult to recognize in the early acute phase and those patient with long-lasting recurring symptoms, recognized in the subacute to chronic phase, may be more refractory or have established a kindled sympathetic positive feedback loop that becomes more difficult to disrupt [21–23].

To our knowledge, this is the first case report of the use of dexmedetomidine to control PAID-related clinical events. Although further study is needed to further elucidate efficacy and clearly define the indications for usage of dexmedetomidine, it appears to be promising, based on its pharmacodynamics. By helping to resolve these clinical events, dexmedetomidine may be a useful pharmacologic tool to hasten the recovery of critically ill neurologic patients.

References

1. Blackman JA, Patrick PD, Buck ML, Rust RS Jr. Paroxysmal autonomic instability with dystonia after brain injury. Arch Neurol 2004;61(3):321–8.
2. Fernandez-Ortega JF, Prieto-Palomino MA, Munoz-Lopez A, Lebron-Gallardo M, Cabrera-Ortiz H, Quesada-Garcia G. Prognostic influence and computed tomography findings in dysautonomic crises after traumatic brain injury. J Trauma 2006;61(5):1129–33.
3. Goh KY, Conway EJ, DaRosso RC, Muszynski CA, Epstein FJ. Sympathetic storms in a child with a midbrain glioma: a variant of diencephalic seizures. Pediatr Neurol 1999;21(4):742–4.
4. Talman WT, Florek G, Bullard DE. A hyperthermic syndrome in two subjects with acute hydrocephalus. Arch Neurol 1988;45(9):1037–40.
5. Boeve BF, Wijdicks EF, Benarroch EE, Schmidt KD. Paroxysmal sympathetic storms ("diencephalic seizures") after severe diffuse axonal head injury. Mayo Clin Proc 1998;73(2):148–52.
6. Baguley IJ, Heriseanu RE, Felmingham KL, Cameron ID. Dysautonomia and heart rate variability following severe traumatic brain injury. Brain Inj 2006;20(4):437–44.
7. Eltorai IM, Wong DH, Lacerna M, Comarr AE, Montroy R. Surgical aspects of autonomic dysreflexia. J Spinal Cord Med 1997;20(3):361–4.
8. Keren O, Yupatov S, Radai MM et al. Heart rate variability (HRV) of patients with traumatic brain injury (TBI) during the post-insult sub-acute period. Brain Inj 2005;19(8):605–11.
9. Bernath O. Treatment of paroxysmal sympathetic storm with labetalol. J Neurol Neurosurg Psychiatry 2001;70(6):818–9.
10. Diamond AL, Callison RC, Shokri J, Cruz-Flores S, Kinsella LJ. Paroxysmal sympathetic storm. Neurocrit Care 2005;2(3):288–91.
11. Do D, Sheen VL, Bromfield E. Treatment of paroxysmal sympathetic storm with labetalol. J Neurol Neurosurg Psychiatry 2000;69(6):832–3.
12. Bullard DE. Diencephalic seizures: responsiveness to bromocriptine and morphine. Ann Neurol 1987;21(6):609–11.

13. Becker R, Benes L, Sure U, Hellwig D, Bertalanffy H. Intrathecal baclofen alleviates autonomic dysfunction in severe brain injury. J Clin Neurosci 2000;7(4):316–9.
14. Cuny E, Richer E, Castel JP. Dysautonomia syndrome in the acute recovery phase after traumatic brain injury: relief with intrathecal Baclofen therapy. Brain Inj 2001;15(10):917–25.
15. Hogue CW Jr., Talke P, Stein PK, Richardson C, Domitrovich PP, Sessler DI. Autonomic nervous system responses during sedative infusions of dexmedetomidine. Anesthesiology 2002;97(3):592–8.
16. Feld J, Hoffman WE, Paisansathan C, Park H, Ananda RC. Autonomic activity during dexmedetomidine or fentanyl infusion with desflurane anesthesia. J Clin Anesth 2007;19(1):30–6.
17. Gurbet A, Basagan-Mogol E, Turker G, Ugun F, Kaya FN, Ozcan B. Intraoperative infusion of dexmedetomidine reduces perioperative analgesic requirements. Can J Anaesth 2006;53(7):646–52.
18. Bicer C, Esmaoglu A, Akin A, Boyaci A. Dexmedetomidine and meperidine prevent postanaesthetic shivering. Eur J Anaesthesiol 2006;23(2):149–53.
19. Oppenheimer SM, Gelb A, Girvin JP, Hachinski VC. Cardiovascular effects of human insular cortex stimulation. Neurology 1992;42(9):1727–32.
20. Oppenheimer SM, Kedem G, Martin WM. Left-insular cortex lesions perturb cardiac autonomic tone in humans. Clin Auton Res 1996;6(3):131–40.
21. Swissa M, Zhou S, Gonzalez-Gomez I et al. Long-term subthreshold electrical stimulation of the left stellate ganglion and a canine model of sudden cardiac death. J Am Coll Cardiol 2004;43(5):858–64.
22. Watt JA, Moffet CW, Zhou X, Short S, Herman JP, Paden CM. Central peptidergic neurons are hyperactive during collateral sprouting and inhibition of activity suppresses sprouting. J Neurosci 1999;19(5):1586–98.
23. Zhou S, Cao JM, Swissa M et al. Low-affinity nerve growth factor receptor p75NTR immunoreactivity in the myocardium with sympathetic hyperinnervation. J Cardiovasc Electrophysiol 2004;15(4):430–7.